



Bapuji Educational Association (Regd.)

SSIMS TIMES



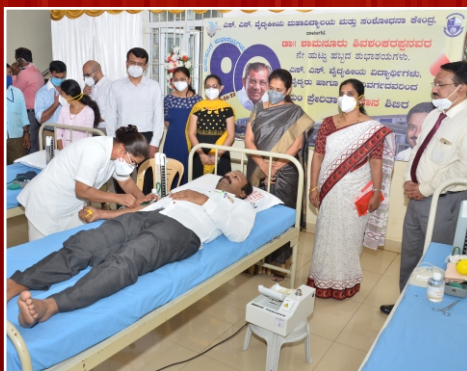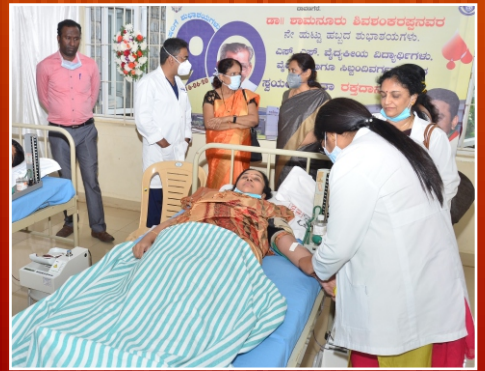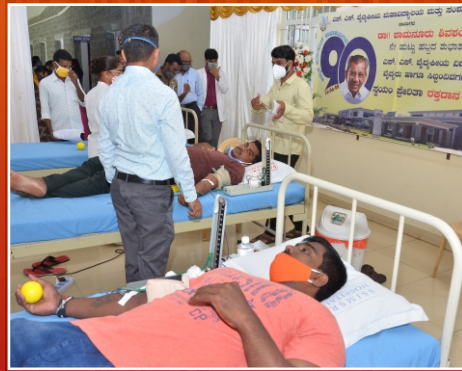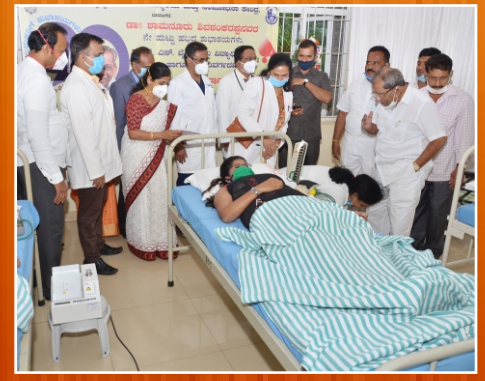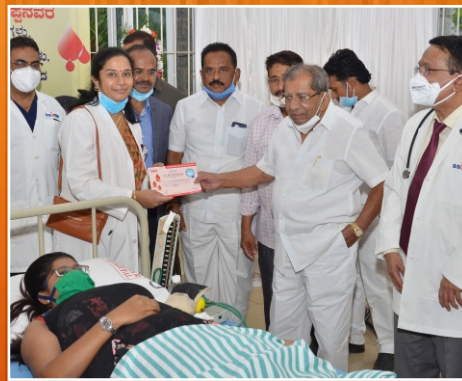Vol: 15 Issue: 2 April - June 2020

Official Quarterly News Bulletin of SSIMS&RC



Inauguration of COVID - 19 LAB





S.S. Institute of Medical Sciences & Research Centre

NEWS BULLETIN COMMITTEE

Editorial Office : DEPARTMENT OF ANATOMY

Extn. Nos. : 08192-266313,

e-mail: ssimstimes4u@gmail.com

Advisory Board:

Dr. B.S Prasad, Principal

Dr. Kalappanavar N.K. Medical Director

Editor in Chief :

Dr. A V Angadi

Prof. and Head

Dept. of Anatomy

Editors :

Dr. Shailaja C. Math

Professor of Anatomy

Dr. Raghavendra A.Y.

Professor of Anatomy

Co-editors

Dr. Santosh M Bhosale

Dr. Nagaraj S Mallashetty

Dr. Veeresh Itagi

Dr. Poornima B.

All the Heads of Dept

Executive members

Dr. A.V. Angadi

Dr. Vidya M. Nadiger

Dr. Mallikarjuna.C.R

Dr. P. Shashikala

Dr. Basavarajappa. K. G

Dr. Kiran L. J.

Dr. Vijayakumar. B. Jatti

Dr. Geethalakshmi R.G.

Dr. Shantala Arunkumar

Dr. Yogeesh B.S.

Dr. Jayaraj S.G.

Dr. Linganagouda S Patil

Dr. Prema Prabhudev

Dr. Manjunath J.

Dr. Arun Kumar. A

Dr. Jagannath Kumar. V

Dr. Narendra. S. S

Dr. K.R. Parthasarathy

Dr. L. Krishnamurthy

Dr. H.B. Shivakumar

Dr. P. Malleesh

Dr. Shivamurthy K.C.

Dr. D'costa

Technical support

Sandeep S. H

Santhosh Kumar. D. M

S. D. A

Photographer

PATRONS



Dr. Shamanur Shivashankrappa

Honorary Secretary, BEA.

MLA, Davangere (South)



Sri. S. S. Mallikarjun

Joint Secretary, BEA.

Chairman, SSIMS&RC

Ex-Minister of Horticulture
& APMC Govt. Of Karnataka.

Contents

Page No.

Principal & Editorial desk

2

Departmental activities

2-5

Events

5

Research Articles / Case Report

6-11

Publications

12

Congratulations

12



SSIMS&RC

NH-4, Bypass Road, Davangere - 577 005.

Phone : 08192-266301,266302,261808.

FAX : 08192-266310.

E-mail : principalssimsrc@gmail.com

Web site : www.ssimsrc.com

Disclaimer :

Views and opinions expressed in this newsletter are not directly that of the editor or the editorial board. For any clarification, author of the article is to be contacted.



Principal's desk

"On behalf of the institution, I would like to convey heartfelt wishes to our beloved **Dr. Shamanur Shivashankarappa**, Honorary Secretary, BEA., MLA, Davangere (South), Ex. Minister of Horticulture & APMC Govt. of Karnataka, on the occasion of the birthday.

I hereby congratulate the newly inaugurated Student Union-2020 and wish them all the best and suggest carrying out various academic and extra-academic activities with great enthusiasm and spirit.

I congratulate all the UG and PG rank holders at the university level and other academic excellence. I also congratulate the students and faculties who are selected for scientific project works under ICMR and RGUHS research units.

I would like to convey my regards to each and everyone who is involved in good and constructive academic, research, curricular activities which helps in taking the institution's name to a new height, highlighting the efforts put forth during this COVID-19 pandemic situation.

I would like to suggest all the heads of Dept. to encourage the faculty and students to carry out more research-oriented activities and take part in academic and extracurricular events.

It's our sincere requests to all the teaching, non-teaching, nursing and domestic staffs to proactively take part in COVID-19 related works in the institution.

Dr. B.S Prasad

Editor's desk



On behalf of the editorial team, I wish a very happy Birthday to our beloved **Shri. Dr. Shamanur Shivashankarappa**.

I extended my whole hearted gratitude to all the faculty members for the over whelming response shown towards bringing out the second issue. I thank each and everyone who has given a great input of information and memories for publication.

This issue is a brief insight to all the happenings of the campus and achievements of various faculties of the Institution.

Dr. A. V. Angadi

Department of Physiology

Dr. Suneeta Kalasuramath, Professor attended online webinar series on online teaching, learning & assessment practices during COVID times conducted by "MAHE FAIMER Alumni global Webinar series" from May 4th to May 30th, 2020.

She also attended the webinar series on "Yoga for Human excellence", conducted by Centre for consciousness studies (NIMHANS) from 22nd to 26th June, 2020. This webinar stressed on physiology & neural basis of meditation / pranayama and cultivating human excellence the meditation way.

Department of Pathology

Webinar on training for Doctors & Pathology professional for COVID- 19 was conducted by RGUHS on Cisco Webex on 30th April 2020. Dr. Shashikala. P, Dr. Kavita G.U, Dr. DeeptiPruthvi, Dr. Balaji T.G, Dr. Nandish V.S attended the webinar.

Webinar on training of Doctors on convalescent plasma therapy for COVID-19 was conducted by RGUHS on Cisco Webex on 14th May 2020. Dr. Shashikala. P, Dr. Kavita G.U, Dr. Deepti Pruthvi, Dr. Balaji T.G, Dr. Nandish V.S attended the same webinar.

Webinar on "CBC interpretation" was conducted by Dr. Chethana Manohar on 20th May 2020. Dr. Shashikala. P, Dr. Kavita G.U, Dr. Deepti Pruthvi, Dr. Neetha. Y, Dr. Rajashree. K, Dr. Balaji T.G, Dr. Nandish V.S, Dr. Sreevidyalatha G.S, Dr. Disha B.S.



Post graduates Dr. Gourav Gosh, Dr. Shilpa R, Dr. Sanjana S.K attended the discussion.

Webinar on "Role of bone marrow biopsy in staging & management of Hodgkin & Non- Hodgkin lymphomas" was conducted by onquest laboratories on 21st May 2020. Dr. Tejender Singh was the speaker and modulated by Dr. Shivali Ahlawat. Dr. Shashikala. P, Dr. Kavita G.U, Dr. Deepti Pruthvi, Dr. Neetha. Y, Dr. Rajashree. K, Dr. Nandish V.S. PG's: Dr. Gourav Gosh, Dr. Shilpa R, Dr. Sanjana S.K attended the discussion.

Voluntary Blood donation camp was organised on the occasion of 90th Birthday of Shri Shamanur Shivashankarappajji, Chairman, Bapuji Education Association on 16th of June 2020 at college office premises. The programme was inaugurated by Shri Shamanur Shivashankarappajji. Vanamahotsava was also celebrated by planting saplings in the office garden quadrangle. About 36 Non- teaching staff and teaching staff of SSIMS&RC donated blood on the occasion. The function was followed by cake cutting by our honourable chairman.



Department of Microbiology

Dr. Jayasimha. V.L, Professor awarded a grant of 20 lakhs for research work on Clinicol Bacteriological study of neonatal septicemia with special reference to sepsis markers, C- Reactive protein and Procalcitonin. VGST, Govt. of Karnataka under K-FIST level-II programme. (KSTEPS/VGST/K-FIST (L2)/2015-16-GRD-473/141/2019-2020/55.

Department of Community Medicine

Dr. Geethalakshmi RG has been selected as member of district level medical expert committee in Davangere district as per the reference circular issued by Additional Chief Secretary, Health and family welfare department to assist the Covid 19 related activities at the district.

Fever clinics to detect patients with high temperature and other symptoms of Covid 19 are set up at SSIMS hospital block and PHC Lokikere, run by Assistant professors and interns on rotation.

RNTCP activities: State task force meet to assess the first and second quarter reports from medical colleges' involvement in RTNCP/NTEP was organized online by the State Task Force, Dept. of Health & Family Welfare, Karnataka on 09/07/2020. The nodal officer Dr. Geethalakshmi R G, and all the other core committee members of NTEP had participated in the meeting.

Department of Pediatrics

Dr. N.K.Kalappanavar, Medical Director, Prof & Head, moderated Session On Clinical "Approach to Respiratory Distress In Day To Day Practice" Conducted By National IAP on 11th June 2020.

Dr. N.K.Kalappanavar participated As Expert In Webinar Conducted By IAP- Karnataka State Chapter on "Current Guidelines For Managing Covi-19 Patients In Clinics And Hospitals" on 23rd June 2020.

Dr. N.K.Kalappanavar participated in "Under 5 Wheezes-National Tot "On 21st June 2020 Conducted By Central IAP.

Dr. N.K.Kalappanavar participated as Panelist in Webinar on "ENT, Issues in Covid times-Challenges and Solutions" on 1st July 2020.



Department of Dermatology

World vitligo Day



ಮನೆಗೆ ಹಲವು ಬಣ್ಣಗಳ ಸಂಯೋಜನೆ
ಹೆಚ್ಚಿದರೆ ಚೆನ್ನಾಗಿರುತ್ತೆ ಎಂದು ಯೋಚಿಸುವ
ನಾವು

ಬಟ್ಟೆಗಳ ಧರಿಸಲು ಹಲವು ಬಣ್ಣಗಳ
ಸಂಯೋಜನೆ ಇರುವ ಬಟ್ಟೆಗಳ ಹುಡುಕುವ
ನಾವು

ಮನೆಯನ್ನು ಅಲಂಕರಿಸಲು ಹಲವು ಬಣ್ಣ
ಬಣ್ಣದ ಸಂಯೋಜನೆ ಇರುವ ವಸ್ತುಗಳ
ಹುಡುಕುವ ನಾವು

ಪ್ರಕೃತಿಯಲ್ಲಿ ಆಗಾಗ ಮೂಡುವ ಬಣ್ಣಗಳ
ಸಂಯೋಜನೆಯ ಸೌಂದರ್ಯವನ್ನು
ಸವಿಯುವ ನಾವು

ನಮ್ಮ ಮೈಮೇಲೆ ನಮಗೆ ಅರಿವಿಲ್ಲದೆ
ಮೂಡುವ ಬಣ್ಣಗಳ ಸಂಯೋಜನೆಯ ಬಗ್ಗೆ
ಯೋಚಿಸಬೇಕೆ ?!

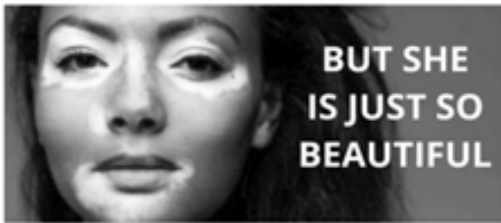ಹೆಮ್ಮೆಯಿಂದಿರಬೇಕು

ಡಾ||ಮಧು ಎಂ
ಚರ್ಮ ರೋಗ ವಿಭಾಗ
ಎಸ್. ಎಸ್. ವೈದ್ಯಕೀಯ
ಮಹಾವಿದ್ಯಾಲಯ, ಸಂಕೋದನಾ ಕೇಂದ್ರ
ದಾವಣಗೆರೆ



The houses are so colourful

The nature is so colourful



Painting looks so colourful

Dresses are so colourful



Dr Madhu M
Department of Dermatology
SSIMS &RC
Davanagere

Department of Psychiatry

IMPACT OF COVID 19 ON MENTAL HEALTH:

The outbreak of COVID 19 pandemic has certainly thrown light on mental health and people have started to take note of it along with physical wellbeing. Department witnessed rise in the number of patients presenting with symptoms of anxiety disorders, depression, alcohol withdrawal, panic attacks and suicide attempts which were all directly related to COVID 19 outbreak and related to lockdown effects. We saw various people from the public who often sought help for undue apprehension and worry due to COVID 19 outbreak. All of these patients were treated suitably with both appropriate pharmacotherapy and counselling and are kept under regular follow up.

TELEGUIDANCE PROGRAM:

Dr. Mruthyunjaya. N, Associate Professor, Department of Psychiatry, SSIMS & RC, Davangere has been a part of Tele-Psychiatry through an initiative called 'COVID 19-TeleGuidance' started by IPS-KC (Indian Psychiatric Society-Karnataka Chapter) and has been actively involved in phone consultations and counselling, thus catering to a number of distant patients since the beginning of the lockdown.

Department of Psychiatry

Dr. Anupbanur , associate professor was appointed to the district level medical expert committee for Covid -19 by district Administration on 10th may 2020.

Dr.Anupbanur attended the state level on E-CME on current place of Glycopyronium in COPD management at the main speaker on 24thjune 2020.

Medical Education Unit

Dr. Anupbanur , associate professor was appointed to the district level medical expert committee for Covid -19 by district Administration on 10th may 2020.

Dr.Anupbanur attended the state level on E-CME on current place of Glycopyronium in COPD management at the main speaker on 24thjune 2020.



Dr. Deepti Pruthvi has participated in the National workshop on "Application of Technology for the implementation of competency Based Medical Education" organised by the Medical Education Unit, Shri Sathya Sai Medical College and Research Institute, in association with Centre for Health Professions Education (CHPE) Sri Balaji Vidyapeeth (SBV), Puducherry held from 4th June to 6th June 2020, conducted online.


CISP-II work shop was held from 2nd July 2020 to 3rd July 2020 by MCI nodal centre JNMC Belgavi- Online. Curriculum implementation support program for second phase faculty. Dr. Deepti Pruthvi, Professor of Pathology and Dr. Veena M Associate Professor of Microbiology, SSIMS & RC attended the workshop.

Events

Birthday celebration of our honorable secretary Shri. Dr. Shamanur Shivashankarappaji

On 16th June 90th birthday of our honorable secretary Shri. Dr. Shamanur Shivashankarappaji was celebrated in the Institution. On this occasion, blood donation camp was arranged by Department of Pathology, Blood bank SSIMS&RC and over 40 volunteers participated and donated blood. On the same day, World environment day was celebrated by planting sapling of 90 plants.

This was witnessed by Dr. B S Prasad, Principal, Dr. N K Kalappanavar, Medical director, Dr. Shashikala Pandr. Arunkumar Ajjappa, vice - principal, Dr. Basavarajappa. Student union-2020 chairman, faculties and students.



COVID 19 LABORATORY INAUGURATION - 9th May 2020

Molecular laboratory wing of the Microbiology department was inaugurated on 9th May 2020 by Minister of Medical Education, Sri Dr K Sudhakar. The function was presided by Hon'ble minister Sri. Dr. Shamanur Shivashankarappa, Secretary BEA. Sri. Bairathi Basavaraj Davangere District Minister, Sri. Siddesh Minister of Parliament, Prof. Sri. Linganna, Sri. Ramachandrappa Jagalur MLA, Sri Maadal Virupakashappa MLA channagiri, Sri. S.A. Ravindranath MLA, Davangere, Sri. Mahanteshbilagi District commissioner Davangere, Hanumantharaya, Sub Inspector, Davangere Dist. were also present. The laboratory is accredited by NABL and approved by ICMR for COVID-19 testing by RT-PCR method. The laboratory is equipped with state of the art equipment required for RT-PCR testing. Dr. B.S. Prasad, principal is the nodal officer for the laboratory, Dr. Basavarajappa Department of Microbiology, Dr. Vinodkumar. CS Director of Molecular laboratory, Dr. Satish Shiva raj Patil Secretary of Molecular laboratory





Case Report

Keratosis diffusafetalis: A rare case report

Dr. Shilpa Nabapure¹, Dr. Rashmi P.S², Dr. Prema Prabhudev³, Dr. Renuka⁴, Asst. Professor, Professor, Professor & HOD, Postgraduate

Abstract Harlequin Ichthyosis is the most severe form of congenital Ichthyosis presenting at birth. It is characterized by thick, fissured armor-plate hyperkeratosis, ears and nose deformities, ectropion, eclabium with fish mouth appearance, flexion deformities of all joints and hypoplastic digits. It is a very rare disorder with autosomal recessive inheritance. Perinatal mortality is high and the survivors develop severe erythroderma subsequently. We report a case of Harlequin Ichthyosis not only because of its rarity but also its tendency to occur in consecutive pregnancies. We recommend to have a genetic screening and counseling in all high risk couples e.g. consanguinity marriages as well as having more studies to diagnose and determine the best mode to deliver a baby with HI.

Conclusion: Early diagnosis and genetic counseling of the parents is an important step in managing Harlequin Ichthyosis. We recommend to have a genetic screening and counseling in all high risk couples e.g. consanguinity marriages, and with family history of Harlequin ichthyosis or previous child born with Harlequin ichthyosis preimplantation genetic diagnosis can be done by screening for ABCA12 gene in both affected baby and parents.

Keratosis diffuse fetalis, Harlequin ichthyosis, gene mutation, congenital autosomal

Introduction

Disorders of cornification (ichthyoses) are a group of rare inherited disorders characterised by the presence of excessive amounts of dry surface scales. It is a disorder of keratinisation or cornification. Abnormal epidermal differentiation or metabolism is the basic pathology in these disorders. Histopathological examination of skin biopsy will show hyperkeratosis in these neonates. Harlequin ichthyosis (HI)/ Keratosis diffusafetalis is the most severe and rare form of congenital ichthyosis.

Since the disease causes considerable amount of disfigurement it may cause profound psychological trauma in parents or other caregivers.

Children who survive post-infancy may face stigmatization and discrimination owing to abnormal appearance of skin. More than 200 cases have been reported throughout the world. Antenatal diagnosis in suspected cases can be confirmed using electron microscopy of fetal skin biopsy and DNA-based diagnosis with chorionic villus sampling or amniocentesis. There is no cure for this condition and only supportive treatment can be given to prolong life.

Case report

A G4P2L2A1 with previous 2 FTVD (Both female babies alive and healthy) aged 26 years registered with a private practitioner, reported to SS institute of medical sciences, labor room with 34 weeks 3 days of gestation with preterm premature rupture of membranes in latent labor with breech presentation. A history of 2nd degree consanguinity was noted. Her ANC was uneventful, anomaly scan done at 22 weeks was normal. Patient and attenders were counselled regarding mode of delivery and they opted for LSCS with tubectomy. She underwent emergency lower segment cesarean section with abdominal tubectomy in view of breech presentation and delivered a female ichthyotic baby weighing 1.9 kg on, July 07 2019. Her postnatal course was uneventful. She was discharged on postnatal day-6 after suture removal.

The baby had white porcelain-like skin covering the body like armor with deep creases all over the body as shown in. Bleeding was noticed from the creases. The baby had a weak cry at birth. Eyelids and lips were everted showing ectropion and eclabion, respectively. Nasal hypoplasia with two nostrils was seen. The mouth was open with thick lips as seen in Figure 1.

The fingers and toes were flexed and fixed flexion deformity noticed, as seen in Figure 3. The ears were small with closed pinna. The heart rate and respiratory rate were normal. The baby was sent to the neonatal intensive care unit for further management. Patient and attenders refused admission to NICU inspite of extensive counselling and further care.

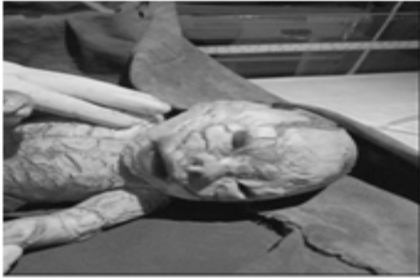

Fig 1: Showing Harlequin fetus with characteristic clown like facies, with ectropion, eclabium and under developed nose. Note the coat of armour like appearance with shiny plates and fissures



Fig 2: The fingers and toes were flexed and fixed flexion deformity, incurved toes, short foot length and clenched fist typical of Harlequin fetus

Discussion

Harlequin ichthyosis is a congenital disorder characterized by an autosomal recessive inheritance and incidence of about 1 in 300,000 births [1]. Usually, it has a fatal prognosis and most of HI babies die in the first weeks of life. Majority of the cases are reported due to ABCA12 gene mutation which is a gene responsible for transporting lipid to the epidermis in order to form a healthy normal skin. Infants at birth usually have thick, fissured armor-plate hyperkeratosis, ears and nose deformities, ectropion, eclabium with fish mouth appearance, flexion deformities of all joints and hypoplastic digits. Furthermore, restricted chest expansion and skeletal deformities may result in respiratory failure. Hypoglycemia, dehydration or even renal failure is common in these patients mainly due to feeding problems. In addition, hypo- or hyperthermia as well as infections are common. Most of these clinical features are present in this case. The hallmarks of the diagnosis are the family history, consanguinity and other skin disorders. In our case also, the couple was consanguineous.

The maternal triple-marker screen is part of the standard clinical obstetric practice and is used routinely to diagnose Down syndrome, trisomy 18, and open neural tube defects. The most common cause for extremely low levels of unconjugated estradiol, one of the markers screened in the triple test, is X-linked ichthyosis. In this condition, there is placental insufficiency of steroid sulfatase, and therefore defective steroidogenesis. In case maternal serum screening reveals isolated low levels of unconjugated estradiol, amniocentesis or CVS sampling must be performed to confirm the suspicion of X-linked ichthyosis. Since there are 25% chances of recurrence in future pregnancies, it is a challenge for the obstetricians and the radiologists to enable timely diagnosis.

Three-dimensional (3D/4D) ultrasonography may show certain features like rudimentary ears, flexion contractures, and floating particles in the amniotic fluid suggestive of Harlequin Ichthyosis. Even if there is no history of HI in the family, features like large and gaping mouth, aplasia of the nose, abnormal limbs, and bulging eyes on 3D scans may help in diagnosis. Two-dimensional ultrasonography can also demonstrate features of harlequin ichthyosis but not until late in the second trimester, when enough keratin buildup is present to be sonographically detectable. Short feet may be an early marker for harlequin ichthyosis [2].

Apart from imaging, fetal skin biopsy also has a role in prenatal diagnosis. On light microscopy, premature keratinization can be identified by 20th to 22nd week. Electron microscopy may show atypical intraepidermal vesicles at 16 weeks. Amniocentesis at 17 weeks may show intracellular lipid vesicles in clump shed keratinocytes [3]. DNA-based prenatal testing by direct sequence analysis and restriction enzyme digestion analysis using fetal genomic DNA from amniotic fluid cells at 16 weeks gestation is also available for HI, and it is the investigation of choice for prenatal diagnosis of this condition. Detailed genetic counseling is therefore required for affected families. Preimplantation genetic diagnosis can be done by analyzing the ABCA12 gene if the family already had a previous child with Harlequin ichthyosis history.



Extended family members should be advised to avoid consanguineous marriages because of the genetic risk. The mortality rate for Harlequin Ichthyosis is high, with worldwide figures approaching 50%.

However, with neonatal intensive care and oral retinoid therapy (acitretin in the dose of 0.5-1 mg/kg/day orally), more babies survive the newborn period than in the past. A topical retinoid (tazarotene) can also be used to treat local and mechanical circulatory problems caused by hyperkeratosis. In a review of 45 cases by Rajpopat et al. it was found that twenty five cases of HI (56%) survived, ranging in age from 10 months to 25 years and there were twenty deaths (44%) from day 1 to day 52 either due to respiratory failure or fulminant sepsis [4].

Conclusion

With improvement in supportive clinical care, the use of oral retinoid and regular moisture of the skin the survival rate of patients with HI has increased. However, early diagnosis and genetic counseling of the parents is an important step in managing such patients. We recommend to have a genetic screening and counseling in all high risk couples e.g. consanguinity marriages, and with family history of Harlequin ichthyosis or previous child born with Harlequin ichthyosis preimplantation genetic diagnosis can be done by screening for ABCA12 gene in both affected baby and parents.

References

1. Sharma CAS et al. Int J Reprod Contracept Obstet Gynecol. 2015; 4(6):2100-2102.
2. Swati Rathore et al., Harlequin Ichthyosis: Prenatal Diagnosis of a Rare yet Severe Genetic Dermatoses JCDR. 2015; 9(11):QD04-QD06.
3. Tahir A, Tariq S, Haider S Ali et al. Ichthyosis Congenita, Harlequin Type: A Fatal Case Report. Cureus. 2018; 10(10):e3524.
4. Rajpopat S, Moss C, Mellerio J, Vahlquist A, Gånemo A, Hellstrom M. Harlequin ichthyosis: a review of clinical and molecular findings in 45 cases. Arch Dermatol. 2011; 147(6):681-6.

Cooled radiofrequency ablation for osteo arthritis knee

A 'Cool' New procedure eases arthritis pain without surgery. Osteoarthritis knee is a painful, sometimes debilitating condition, which reduces the quality of life. It affects approximately 40% of Indian population. Patients try unsuccessfully for years to manage pain with medications like NSAIDs, acetaminophen, homeopathy, topical application of herbs and lotion, even Intra articular injection before they land up in surgery (total knee replacement). Medications like NSAIDs and other analgesics have a major risk of long term cardiac, renal and gastrointestinal complications. Some patients are even put on oral opioids carrying serious side effects such as respiratory depression. Intra articular steroid injections provides short term relief of pain, cannot be given multiple times and are not safe in Diabetic patients.

There are various reasons why patients do not undergo total knee replacement- apprehension about undergoing surgery and the pain, the staggering cost of total knee replacement and added risk of surgical complications. The common statement by a patient is "somehow we will manage to pull on".

This novel treatment called Cooled Radiofrequency ablation of knee joint is an FDA approved, clinically proven method to relieve pain of osteoarthritis of the knee joint for a period of 1½-2 years or more. This is an Outpatient procedure, economical, done under local infiltration (no need of anaesthesia), and patient can walk home the very same day.

The management of S.S Hospital, Dr. Shri Shamanur Shivashankarappa and S.S Mallikarjun have been gracious enough to procure the machine at a cost of 40 lakhs. The service is being made available at the lowest cost possible to ensure that a lower economic status is not a barrier for pain relief. We have started doing the procedure on patients with osteoarthritis knee pain at our hospital with very promising results and satisfied patients



A case of Severe maxillofacial injury with Avulsion of medial canthal System Rt Eye:

Dr. K.C. Shivamurthy Professor and HOD, Dr. Naga Srikanth S Post Graduate , Dept. Of Plastic surgery

Case Report:

Mr.Pavan Kumar 28y/M met with RTA on 30/6/20 due to hit by lorry while travelling in bike. He was admitted Under neurosurgery for initial head Injury management and Later referred to plastic Surgery for the management of Facial Injuries,

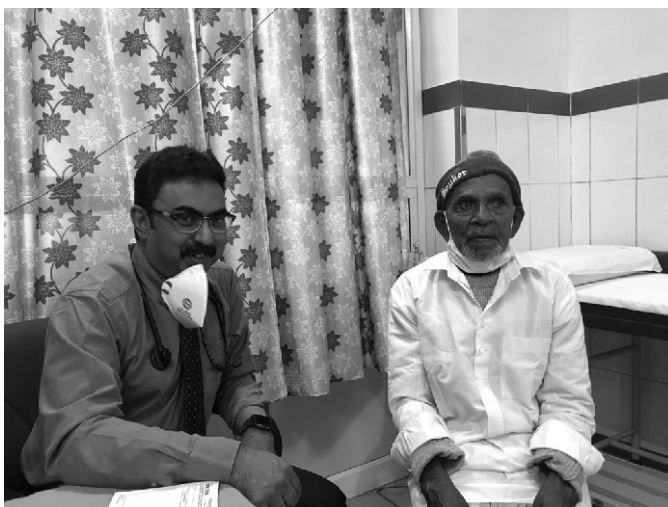He has injury over the mid face with avulsion of right nostril part of nose,disruption of upper lip in the middle and avulsion of the medial canthal apparatus of upper and lower eye lids and Right Knee degloveinjury.With H/o loss of consciousness present, H/o nose and oral bleed present. No H/o vomiting and Ear bleed

Examination : Patient conscious , coherent, and well oriented with vitals within normal limits

Local Examination : There is a Deglove injury of right half of nose with laceration of alae and nostril , upper lip midline split laceration and Disruption of the medial canthal apparatus, visible fractured segments of the Right maxilla and Inferior orbital wall, anterior maxillary wall in to pieces. There is deglove injury over the right knee present with exposed patella.

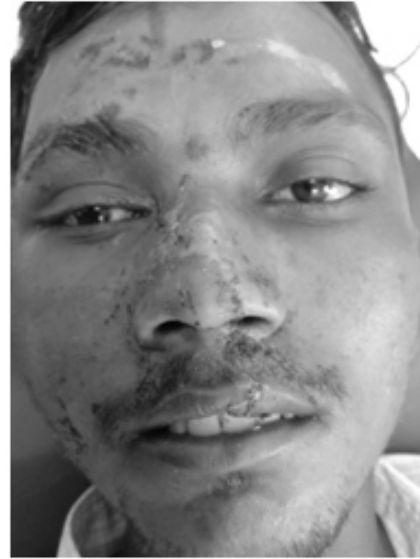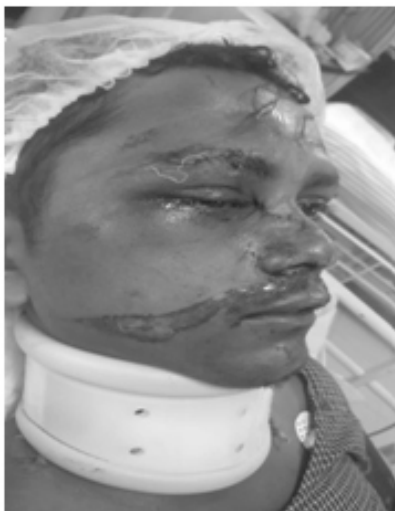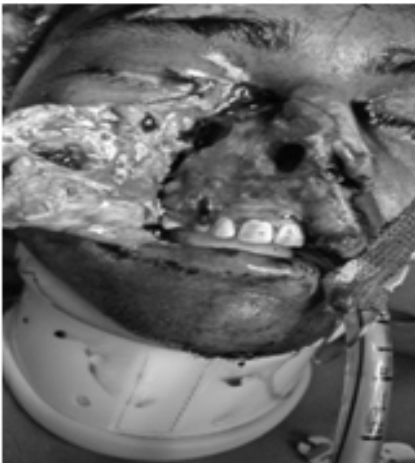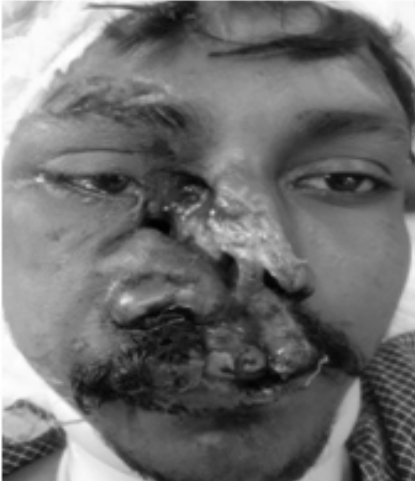CT scan Report : Fracture of the right Maxilla and over Right Inferior orbital wall , Mild extra axial haemorrhage at frontoparietal region

Patient was admitted and stabilised and immediately taken to surgery, Fixed the maxilla fractures with titanium plates , repaired the medial canthal ligament fixed to periosteum, Repaired the nasal alae, repaired the oral mucosa, repaired the Lip laceration in layers.



Post operatively patient recovered well and wounds healed well.

Discussion : Early surgery of the Facial wounds helps in healing and prevent necrosis of the Skin flaps , and prevent infection. Early fixation of facial bones are easy because of less muscle spasm



DAPSONE IN CUTANEOUS VASCULITIS

Dr. Jagannath Kumar V, Prof & HOD, Dr. ManjunathHulmani, Professor, Dr. Madhu M, PG

Introduction:

Cutaneous vasculitis is an inflammatory process affecting the vessel wall that leads to its damage and subsequent haemorrhagic features. It may be a primary disorder or a presenting sign of primary systemic vasculitis such as polyarteritis nodosa, Wegener's granulomatosis, Churg Strauss syndrome or secondary to drugs, infections or systemic diseases such as connective tissue disease and malignancy. Skin is involved in both small vessel vasculitis and medium vessel vasculitis.

Dapsone is an aniline derivative belonging to the group of synthetic sulfones. It has a dual mechanism of action where it has anti-bacterial/ anti-protozoal action as well as anti-inflammatory action where it inhibits predominantly neutrophil chemotaxis. For recurrent and persistent cutaneous vasculitis Dapsone when given early has proved to produce complete resolution of symptoms.

Case report:

A middle aged lady in her early 40s presented to skin OPD with painful skin lesions over the lower limbs progressing to the abdomen since 2 days. She also complained of raised body temperature and myalgia with arthralgia a day prior to onset of rash. On physical examination there were brownish red macules which were non-blanchable on diascopy, multiple in number distributed discretely over the lower limbs extending up to the abdomen. On investigation, leukocytosis (14600 cells/cumm) predominantly of neutrophilic origin was seen. Histology showed leukocytic infiltration around the post-capillary venules in the dermis predominantly composed of polymorphonuclear cells along with fibrinoid deposits around the vessel wall. Extravasated RBCs were seen.

She was advised complete bed rest and was put on oral dapsone 100 mg daily along with oral Methylprednisone which was tapered gradually. Improvement was seen within a day and complete resolution of lesions were noticed within 3 days.

Discussion:

Cutaneous vasculitis was described for the first time by Zeek as a hypersensitivity vasculitis to drugs. It includes three types.

1. Essential mixed cryoglobulinemia
2. Normo-complementemic urticarial vasculitis
3. Acute hemorrhagic oedema of infancy.

Most common etiological causes include infections, drugs, associated connective tissue diseases, malignancy and immune deficiency. Common drugs that induce vasculitis are

1. Penicillins
2. Sulfonamides,
3. Allopurinol,
4. Others include Thiazides, Retinoids, Quinolones, Hydantoin, and Non-steroidal anti-inflammatory drugs

In a cross-sectional study on 60 vasculitis cases done by Khetan P et al.¹ drugs were found to be the most common etiological agent. Another study done in Kuwait showed infections and connective tissue disease as the most common etiological agents.²

Immune complex deposition in blood vessels along with Complement activation, Anti-neutrophil cytoplasmic antibodies, Vascular endothelial cell and Cell-mediated immunity play a role in pathogenesis of vasculitis.

Conclusion:

It is a benign self-limiting condition in most cases. But it is also important to look for the cause before starting treatments. Dapsone is the safest long-term use drug known to mankind which has steroid-sparing and CNS protective effects. Currently, no other drug used in medicine possesses such a wide variety of beneficial properties.

References:

1. Khetan P, Sethuraman G, Khaitan BK, et al. An aetiological & clinicopathological study on cutaneous vasculitis. *Indian J Med Res.* 2012;135(1):107-113. doi: 10.4103/0971-5916.93432
2. Ekenstam E, Callen JP. Cutaneous leukocytoclastic vasculitis. Clinical and laboratory features of 82 patients seen in private practice. *Arch Dermatol.* 1984;120:484-9.

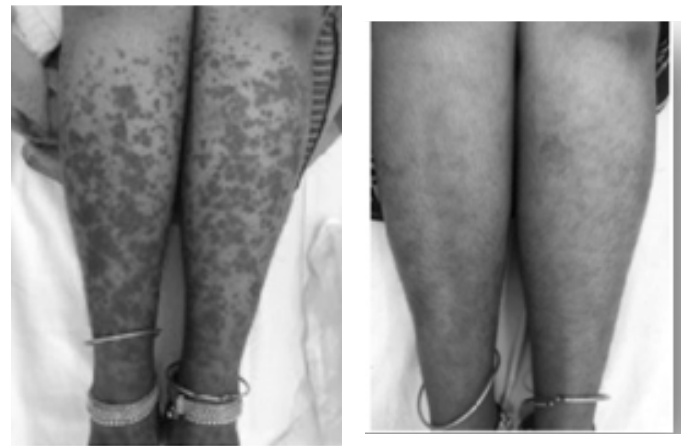

Figure 01: Before starting Dapsone, Figure 02: After 3 days of dapsone therapy.



Publications

Sl. No.	Authors	Title of the publication	Journal/ Citation
1.	Shailaja C Math, Shobha, Vijayakumar BJ , Pravinkumar NK	Clinical and cytogenetic study of Turner syndrome and its variants	Int J Anat Res 2020, Vol 8(2.1):7440-44. ISSN 2321-4287
2.	Raghuprasada M. S., Deepapatil, Shankar A.S Kiran L. J. Shivashankaramurthy K. G., Harish Kumar V. S.,	Pattern of Drug utilization and Factors Influencing long term blood pressure control among hypertensive in a tertiary care hospital-An observational study.,	WJPR/17998/9/2020
3.	Rakesh M Marigouder Chinmay ChandrakantHunugand Arun M	Study of fingerprint patterns among south Indian Population-A cross sectional study	International Journal of Forensic Medicine2020 Vol: 15(1) :1-6.

Congratulations

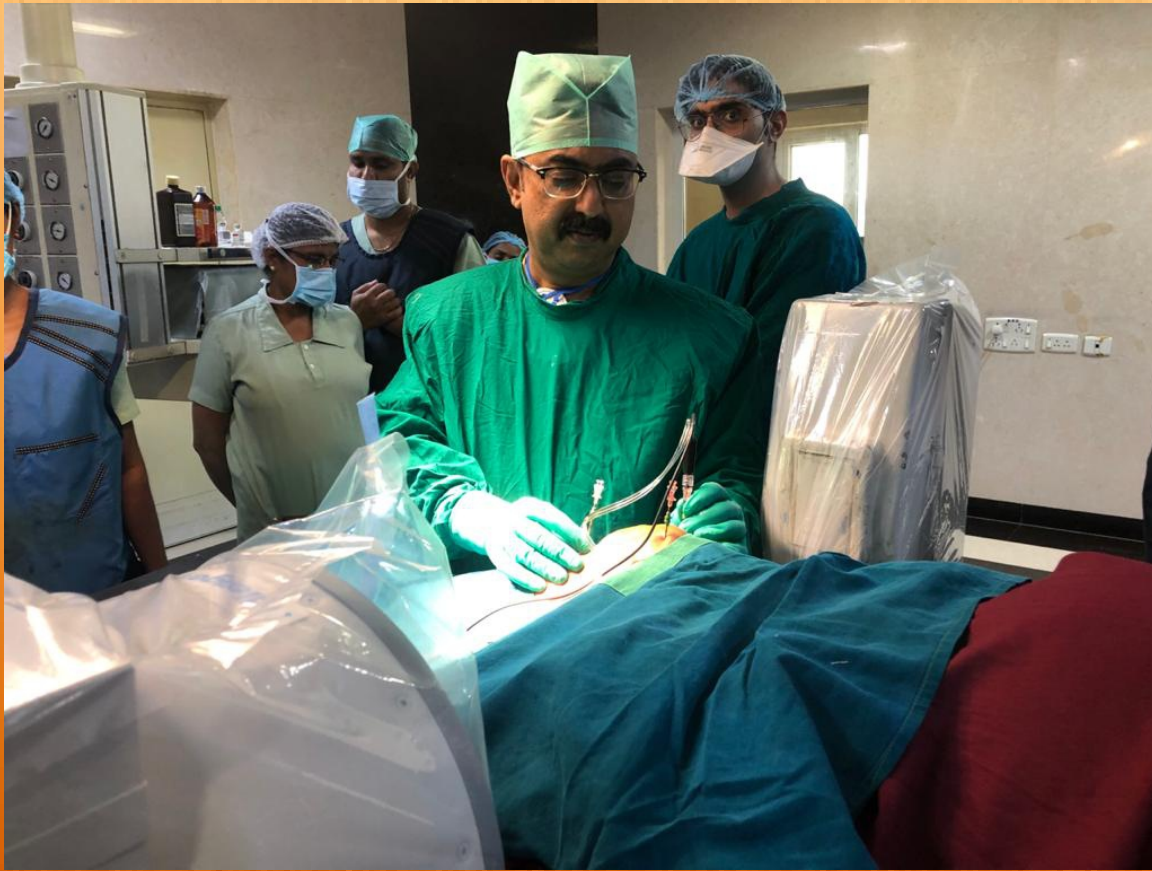

Dr.B.S.Prasad, Principal,Professor,Department of Paediatrics for successful completion of the course MRCPCH Clinical Examiner Training e-Modules certified by Royal College of Paediatrics and Child Health.



Dr. Jayasimha.V.L, Professor awarded a grant of 20 lakhs for research work on Clinical Bacteriological study of neonatal septicemia with special reference to sepsis markers, C- Reactive protein and Procalcitonin. VGST, Govt. of Karnataka under K-FIST level-II program

Photo Gallery



DEPARTMENT OF DERMATOLOGY
SHYAMANURU SHIVASHANKARAPPA INSTITUTE OF MEDICAL SCIENCES & RESEARCH CENTRE, DAVANGERE.



Two coloured skin is not a sin

Vitiligo is a disease with white patches. It is due to the death of the pigment cells in the skin. So may lead to early greying of hair and skin cancer. Treatment options include medications, light & laser therapy and Surgery. LOVE & SUPPORT is the best medicine.

VITILIGO

Scanned with CamScanner

By: Dr. G. R. R. Reddy
SSIMS & RC, Davangere

DEPARTMENT OF DERMATOLOGY
SHYAMANURU SHIVASHANKARAPPA INSTITUTE OF MEDICAL SCIENCES & RESEARCH CENTRE, DAVANGERE.

The Mental and Medical Journey of Living with Vitiligo - The Journey Starts with Me!



When we can Appreciate the colours of Nature, WHY CAN'T WE ACCEPT THE COLOURS OF skin

WORLD VITILIGO DAY
JUNE 15

- DR. KIRAN M S
2ND YEAR PG
SSIMS & RC, DAVANGERE

Inauguration of COVID - 19 RTPCR LAB



District Level Medical Expert Committee

